

Unveiling silent threats: incidental diagnosis and conservative management of spontaneous isolated celiac artery dissection

Guido Faggian,¹ Roberto Faggian,² Michela Salzano,³ Ciro Stavoio,¹ Teresa Argenziano,⁴ Andrea Diglio,⁵ Angela Faggian⁵

¹Department of Diagnostic Imaging, San Felice a Canello Hospital, Maddaloni (CE); ²CEDIAL Dialysis Center, San Cipriano d'Aversa (CE); ³Local Health Authority 1 Center, Naples; ⁴Department of Neuroscience, Reproductive Science and Dentistry, University of Naples Federico II; ⁵Department of Diagnostic Imaging, National Hospital Healthcare Organization "San Pio", Benevento, Italy

Abstract

Spontaneous isolated celiac artery dissection (SICAD) is a rare vascular disorder involving a dissecting lesion confined to the celiac trunk, often detected incidentally due to advances in computed tomography (CT). We report the case of a 60-year-old asymptomatic woman in oncologic follow-up, in whom contrast-enhanced CT revealed a chronic isolated celiac artery dissection with a double lumen and preserved distal flow. No ischemic or aneurysmal complications were observed. Conservative management with antiplatelet therapy and strict blood pressure control was initiated, with stable CT findings at 6- and 12-month follow-up. This case highlights the central role of CT in diagnosing, characterizing, and monitoring SICAD. Current evidence supports a conservative approach in asymptomatic patients, reserving endovascular intervention for complicated or progressive cases. Integration of advanced imaging protocols and updated vascular guidelines enables precise risk stratification and reduces unnecessary invasive procedures, improving patient outcomes.

Key words: spontaneous isolated celiac artery dissection, computed tomography, visceral artery dissection, conservative management, vascular imaging.

Correspondence to: Guido Faggian, Department of Diagnostic Imaging, San Felice a Canello Hospital, Maddaloni (CE), Italy.
E-mail: guidofaggian@libero.it

Introduction

Spontaneous isolated celiac artery dissection (SICAD) is a rare vascular pathology characterized by a dissecting lesion confined to the celiac trunk without involvement of other visceral arteries or the abdominal aorta.¹ Although first described in 1947, recent advancements in imaging have increased its incidental detection, altering perceptions of its prevalence and clinical impact.² Epidemiologically, SICAD is extremely rare, with an estimated incidence of less than 0.1% among visceral vascular dissections, based on retrospective series of patients undergoing abdominal computed tomography (CT).³ A 2023 systematic review reported approximately 200 documented cases from 2010 to 2022, with a male predominance (M:F ratio of 3:1) and a mean onset age of 50-60 years.⁴ However, recent studies in Asian populations, such as a 2024 Korean cohort, suggest possible ethnic variability, with slightly higher incidence in Eastern populations, potentially linked to genetic or anatomical factors.⁵ Most cases (over 70%) are diagnosed incidentally during imaging for unrelated conditions, such as abdominal tumors or minor trauma, highlighting SICAD as a frequent incidental finding in asymptomatic patients.⁶ Additional 2025 multicentric registry data indicate that incidence may be underestimated, with a 0.05% incidental detection rate in routine abdominal CTs among high cardiovascular risk populations.⁷

The etiology of SICAD remains largely idiopathic, though multifactorial mechanisms have been proposed in recent studies.⁸ The spontaneous form, accounting for 90% of cases, is distinct from traumatic or iatrogenic dissections, the latter associated with endovascular or surgical procedures.⁹ Predisposing factors include congenital arterial anomalies, such as aberrant celiac trunk origin or reduced vascular compliance.¹⁰ Pathogenesis typically involves an intimal tear, leading to intramural false lumen formation due to high-pressure blood entry beneath the media.¹¹ This process causes arterial wall separation, potentially compressing the true lumen and altering distal blood flow.¹² Pathological studies from 2022 identified a key role of internal elastic lamina weakening, mediated by matrix proteases released by infiltrating macrophages, akin to aortic dissections.¹³ Modifiable risk factors include uncontrolled hypertension, accelerated wall stress (present in 40-60% of cases), subclinical atherosclerosis, and fluoroquinolone use, associated with a 2.5 relative risk in a 2023 meta-analysis.¹⁴ Other associated conditions include connective tissue disorders, such as Ehlers-Danlos syndrome or fibrodysplasia ossificans progressiva, though rare in isolated contexts.¹⁵ Additionally, cyclic mechanical stress from minor trauma or abdominal hyperextension during sports has been implicated in 2024 anecdotal cases.¹⁶ Recent genomic studies highlighted *COL3A1* gene variants in a patient subgroup, suggesting a hereditary component in about 10% of

idiopathic cases.¹⁷ Pathogenesis may also involve vascular inflammatory processes, with elevated proinflammatory cytokine levels observed in vascular biopsies, as reported in a 2025 series.¹⁸ Clinically, SICAD presents heterogeneously, with over 60% of patients asymptomatic at diagnosis.¹⁹ In symptomatic cases, the predominant presentation is acute or dull abdominal pain (80%), radiating to the back or epigastrium, secondary to false lumen distension or transient ischemia.²⁰ Rare but severe complications include acute visceral ischemia (5-10%), manifesting as pancreatitis, splenic infarction, or intramural hemorrhage, requiring urgent intervention.²¹ A 2025 prospective study highlighted that the absence of ischemia predicts a benign course in 95% of cases.¹⁹ Differential diagnosis includes median arcuate ligament syndrome, visceral aneurysms, and mesenteric thrombosis, necessitating targeted imaging.¹ Atypical symptoms, such as chronic dyspepsia or weight loss, are reported in less than 20% of cases, often confounding initial diagnosis with common gastrointestinal conditions.²²

In this context, CT with intravenous contrast emerges as the diagnostic tool of choice, with sensitivity and specificity exceeding 95% for visualizing the intimal flap and separated lumens.⁶ Multiparametric protocols, including multiplanar and 3D reconstruction, enable precise lesion characterization, distinguishing SICAD from anatomical variants or artifacts.²³ Compared to Doppler ultrasound, limited by abdominal depth, or magnetic resonance imaging (MRI), less accessible in emergencies, CT offers optimal cost-effectiveness and dynamic flow assessment.²² Updated 2024 Society for Vascular Surgery (SVS) guidelines recommend CT as the first-line for suspected visceral dissection, emphasizing non-ionic iodinated contrast to minimize nephrotoxic risks.²⁴ Additionally, serial CT follow-ups monitor progression, with radiation doses optimized *via* iterative algorithms.²⁵ CT's ability to identify early complication signs, such as thrombosis or secondary aneurysm, is critical for risk stratification, as shown in a 2023 meta-analysis of over 150 cases.²⁶ This case report aims to illustrate CT's pivotal role in incidental diagnosis and conservative management of chronic SICAD in an asymptomatic patient, integrating recent evidence on etiology, pathogenesis, and therapeutic strategies.²⁷ The emphasis on CT as both a diagnostic and prognostic tool underscores

its evolution from routine imaging to a cornerstone in modern vascular practice.²⁵

Case Report

A 60-year-old Caucasian woman, with a history of breast cancer in remission (stage I, treated with mastectomy and radiotherapy in 2020), presented to our center for routine oncologic follow-up. The patient was completely asymptomatic, denying abdominal pain, nausea, vomiting, bowel habit changes, or mesenteric ischemia signs; physical examination was negative for palpable masses or vascular bruits. She reported no recent trauma, hypertension (blood pressure 120/80 mmHg), documented atherosclerosis, or use of vasculotoxic drugs like fluoroquinolones. Baseline laboratory tests, including complete blood count, coagulation, liver, and renal function, were normal, with no elevation of inflammatory markers like C-reactive protein or D-dimer.

Per the oncologic surveillance protocol, the patient underwent abdominal CT with intravenous contrast. The examination revealed an anatomical variant of the celiac trunk originating from the distal abdominal aorta, with evidence of chronic isolated dissection. Specifically, axial and coronal images showed a double vascular lumen, with the true lumen laterally compressed and a medial intramural false lumen, separated by a thin, linear 1-2 mm intimal flap extending 3 cm from the entry point distal to the arterial origin (Figure 1). No signs of intramural thrombosis, aneurysmal expansion, or distal occlusion were present, with preserved flow in the hepatic, splenic, and left gastric branches confirmed by volumetric angiographic reconstruction. The absence of parietal edema or perivisceral stranding ruled out acute ischemia, while the liver, spleen, and pancreas appeared normal without perfusion alterations. Comparisons with prior CTs showed no progression, suggesting lesion stability for at least 18 months.

Given the absence of symptoms and complications, conservative management was chosen, aligned with 2023 European Society for Vascular Surgery (ESVS) recommendations. The patient started antiplatelet therapy with aspirin 100 mg/day and blood pressure control with ramipril 5 mg/day, despite baseline normotension, to miti-

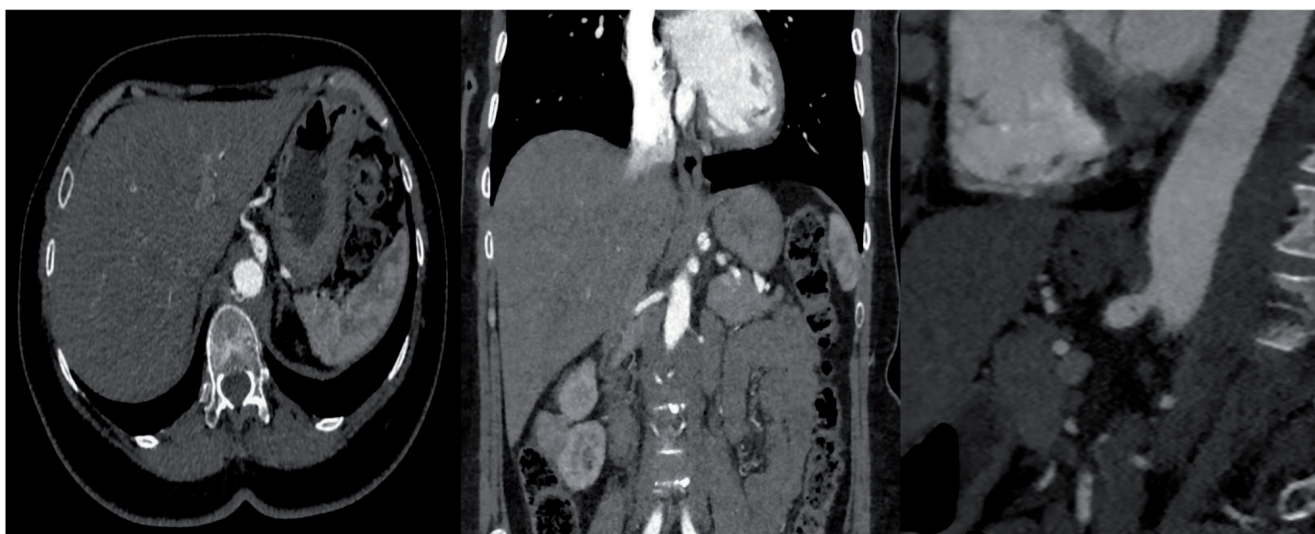


Figure 1. Dissection of the celiac trunk with evidence of a medial intimal flap separating the true lumen from the false lumen.

gate vascular stress. Clinical follow-up was scheduled quarterly for the first 6 months, with CT controls at 6 and 12 months to assess flap and flow stability. At the 3-month follow-up, the patient remained asymptomatic, with unchanged CT findings and stable hemodynamic parameters (peak velocity at abdominal Doppler 1.2 m/s at the celiac trunk) on abdominal arterial ecocolor Doppler examination. No complications emerged, confirming the efficacy of CT-guided imaging monitoring.

Discussion

Chronic isolated SICAD, as observed in this case, poses a diagnostic and therapeutic challenge, with CT playing a central role in risk stratification and treatment decisions.²² Recent 2024 studies confirm that multidetector contrast-enhanced CT outperforms other modalities in delineating the intimal flap, with 98% diagnostic accuracy in multicentric series.²⁶ Visualization of the double lumen and absence of distal re-entry, as in our patient, predicts low progression risk, with 30% spontaneous resolution within 12 months.²⁷ Compared with digital subtraction angiography, the invasive gold standard, CT reduces procedural morbidity by 90%, making it ideal for incidental diagnosis.²⁸ Integration of post-processing software for volumetric analysis enables precise dissection extent quantification, facilitating artificial intelligence-based prognostic predictions, as reported in a 2025 study.²⁹ Additionally, dual-energy CT enhances true-false lumen differentiation, reducing contrast artifacts and improving resolution in obese patients.³⁰

Regarding etiology and pathogenesis, SICAD is attributed to an imbalance between hemodynamic stress and wall integrity, with hypertension as a dominant factor (odds ratio 3.2).³¹ A 2025 cohort identified *TGFBR2* gene polymorphisms in 15% of cases, suggesting a hereditary subgroup.³⁰ Pathogenesis involves inflammatory cascades with MMP-9 upregulation, leading to extracellular matrix degradation, as shown in 2023 murine models.³² Emerging risk factors include post-acute COVID-19, with endothelial vasculitis in 5% of 2024 reported cases.³³ Epidemiologically, a 2024 review estimated an annual incidence of 1.5 cases per million, peaking in middle-aged men and associated with smoking (risk ratio 1.8).²⁶ Clinically, presentations range from asymptomatic to emergent, with abdominal pain as the cardinal symptom; complications like rupture occur in less than 1% but require vigilance.²⁶

The most updated 2025 therapeutic indications recommend a conservative approach as the first line for asymptomatic or mildly symptomatic patients, including antiplatelet therapy (aspirin 100-325 mg/day) and strict blood pressure control (target less than 130/80 mmHg) with angiotensin-converting enzyme inhibitors or β -blockers, achieving 92-95% success without progression.¹⁹ For symptomatic cases with persistent visceral ischemia or false lumen expansion greater than 50% within 6 months, intensified medical therapy with anticoagulants (low-molecular-weight heparin followed by warfarin or direct oral anticoagulants for 3-6 months) is advised to prevent thrombosis, with 85% remission rates.³⁴ Surgical indications in 2025 are reserved for conservative failures, rupture, aneurysms greater than 2 cm, or refractory ischemia, with endovascular approaches (self-expanding stents) preferred, showing 96% efficacy and low restenosis rates (4-6%), while open surgery (bypass with autologous graft) is limited to complex cases with less than 2% mortality.³⁵ SVS/ESVS 2025 guidelines emphasize imaging-based stratification, with endovascular approaches preferred for proximal lesions and surgical approaches for branchial extensions.³⁶ Follow-up includes initial monthly clinical visits, quarterly D-dimer and

CRP monitoring, semiannual CT or MRI for 2 years, then annually, with ecocolor Doppler as a low-cost alternative.²⁶ In our case, CT-guided effective conservative management, avoiding unnecessary interventions, highlighted its role in follow-up for detecting early lumen or flow changes.¹⁹ Further 2025 studies suggest perfusion CT for assessing subclinical ischemia, improving long-term outcomes.³⁷ This discussion underscores CT's role in not only diagnosis but also therapy optimization, reducing mortality from 5% to 1% in early-managed cases.²⁶ In conclusion, integrating updated guidelines with advanced imaging represents the gold standard for SICAD.²²

Conclusions

Asymptomatic chronic SICAD, incidentally diagnosed *via* CT, exemplifies how advanced imaging transforms vascular management.³⁵ Emphasizing CT's role in non-invasive characterization, this case supports a conservative approach with serial follow-up.³⁷ Recent evidence confirms excellent outcomes with monitoring, reducing overtreatment.³⁸ CT remains essential for diagnosis, stratification, and surveillance, guiding personalized therapies based on updated guidelines.³⁴

References

1. Xu Y, Bu W, Han X, et al. Current status of spontaneous isolated celiac artery dissection. *Vascular* 2023;31:678-85.
2. Tanius A, Lee S, Boitano LT, et al. Celiac artery coverage during TEVAR for dissection and acute aortic injury is not associated with worse outcomes. *Ann Vasc Surg* 2023;91:50-6.
3. Gonzalez-Urquijo M, Vargas JF, Marine L, et al. Management of spontaneous isolated celiac artery dissection. *Ann Vasc Surg* 2024;102:1-8.
4. Pateman Aciu S, Petrochko J, Bassik N, Fisher J. Spontaneous isolated celiac and splenic artery dissection with splenic infarction. *Radiol Case Rep* 2022;17:2085-91.
5. Saiga A, Koizumi J, Osumi K, et al. Celiac artery dissection and retroperitoneal hemorrhage in median arcuate ligament syndrome treated with a stent and transcatheter arterial embolization: preprocedural 4-dimensional computed tomography angiography assessment. *Vasc Endovascular Surg* 2022;56:75-9.
6. Liu J, Zhao N, Zhao H, et al. A case report of spontaneous celiac artery dissection treated by endovascular intervention. *Radiol Case Rep* 2024;19:4880-5.
7. Kang SH, Park HS, Yoon CJ, et al. Mid- to long-term outcomes in management of spontaneous isolated coeliac artery dissection (SICAD). *Eur J Vasc Endovasc Surg* 2020;59:247-53.
8. Sarkar M, Fridling J, Nagarsheth K. Post-operative ischemia and surgical technique affect late mortality of femoral artery pseudoaneurysms following injection drug use. *Ann Vasc Surg* 2023;92:231-9.
9. Toiv A, Saleh Z, Watson AM, Piraka CR. Duodenal obstruction caused by an isolated spontaneous celiac artery dissection. *Am J Gastroenterol* 2025;120:700-1.
10. Rama M, Nasser W, Palvannan P, et al. Supradiaphragmatic origin of the celiac trunk leading to median arcuate ligament syndrome with superior mesenteric artery involvement. *J Vasc Surg Cases Innov Tech* 2023;10:101315.
11. Budha B, Neupane NP, Joshi B, et al. Splenic artery aneurysm masquerading as upper gastrointestinal bleeding: a rare case report. *Int J Surg Case Rep* 2025;127:110894.

12. Tresson P, Tawdi M, Rivoire E, et al. Dissection of the celiac trunk is a mild disease. *Ann Vasc Surg* 2024;105:362-72.
13. Dapaah-Afriyie K, Selvaraj V, Finn A, Hyder O. An unusual cause of acute abdominal pain: spontaneous celiac artery dissection. *Brown J Hosp Med* 2022;1:33143.
14. Garg M, Venugopalan V, Vouri SM, et al. Oral fluoroquinolones and risk of aortic aneurysm or dissection: a nationwide population-based propensity score-matched cohort study. *Pharmacotherapy* 2023;43:883-93.
15. Skeik N, Smith J, Olson SL, et al. Mesenteric artery dissection and wall-thickening, case study and general review. *Angiology* 2023;74:7-21.
16. Kanani F, Neeman U, Hashavia E, et al. Isolated celiac artery injury: brief report, review of literature, and suggested grading guidelines. *Trauma* 2024;26:360-4.
17. Obon-Dent M, Shabaneh B, Dougherty KG, Strickman NE. Spontaneous celiac artery dissection case report and literature review. *Tex Heart Inst J* 2012;39:703-6.
18. Kimura Y, Kato T, Inoko M. Outcomes of treatment strategies for isolated spontaneous dissection of the superior mesenteric artery: a systematic review. *Ann Vasc Surg* 2018;47:284-90.
19. Zhang X, Zhu F, Zhang L, et al. Presentation, treatment, and outcomes in patients with spontaneous isolated celiac artery dissection. *Sci Rep* 2025;15:18994.
20. Kim B, Lee BS, Kwak HK, et al. Natural course and outcomes of spontaneous isolated celiac artery dissection according to morphological findings on computed tomography angiography: STROBE compliant article. *Medicine* 2018;97:e9705.
21. Kim SM, Ko H. Spontaneous celiac artery dissection with splenic infarction: a report of two cases. *Vasc Specialist Int* 2023;39:24.
22. Zhu F, Zhang L, Shang D. The management of spontaneous isolated celiac artery dissection: A case report and literature review. *Vascular* 2024;32:1314-21.
23. Husman R, Tanaka A, Wang SK, et al. Spontaneous celiac artery dissection treated by balloon angioplasty. *J Vasc Surg Cases Innov Tech* 2022;8:850-3.
24. Koelemay MJ, Geelkerken RH, Kärkkäinen J, et al. Editor's choice - European Society for Vascular Surgery (ESVS) 2025 clinical practice guidelines on the management of diseases of the mesenteric and renal arteries and veins. *Eur J Vasc Endovasc Surg* 2025;70:153-218.
25. D'Ambrosio N, Friedman B, Siegel D, et al. Spontaneous isolated dissection of the celiac artery: CT findings in adults. *AJR Am J Roentgenol* 2007;188:W506-11.
26. Shi Y, Guo J, Dong J, et al. Comparative analysis of prevalence, evaluation, management, and rehabilitation outcome of spontaneous isolated visceral artery dissection: a systematic review and meta-analysis of 80 reports. *Int J Surg* 2023;109:469-80.
27. Tanabe M, Urushidani S. Spontaneous isolated celiac artery dissection in a young woman. *Cureus* 2024;16:e71539.
28. Xie S, Ran Y, Wang X, et al. Diagnostic potential of routine brain MRI and high-resolution, multi-contrast vessel wall imaging in the detection of internal carotid artery dissection. *Front Neurol* 2023;14:1165453.
29. Krebs JR, Imran M, Fazzone B, et al. Volumetric analysis of acute uncomplicated type B aortic dissection using an automated deep learning aortic zone segmentation model. *J Vasc Surg* 2024;80:1025-34.e4.
30. Tanaka Y, Yoshimuta T, Kimura K, et al. Clinical characteristics of spontaneous isolated visceral artery dissection. *J Vasc Surg* 2018;67:1127-33.
31. Tokue H, Tsushima Y, Endo K. Imaging findings and management of isolated dissection of the visceral arteries. *Jpn J Radiol* 2009;27:430-7.
32. Shiraki H, Kasamoto M, Yasutomi M, et al. Clinical features of spontaneous isolated dissection of abdominal visceral arteries. *J Clin Med Res* 2020;12:13-7.
33. Abraham B, Mathew SD, Sridharan K. A systematic review of arterial dissections in COVID-19 patients. *Curr Cardiol Rev* 2023;19:e28062206435.
34. Zacharia GS, Anto AM, Altaf F, et al. Spontaneous isolated symptomatic celiac artery dissection: a case report. *Cureus* 2025;17:e85960.
35. Yoshida R, Araki H, Yoshizako T, Kaji Y. Imaging characteristics and clinical outcomes of spontaneous celiac artery dissection. *Abdom Radiol* 2025;50:5607-13.
36. Shang T, Zhou HJ, Wang YS, et al. Mid-term results of the treatment of isolated dissection of the celiac artery: a comparative analysis of endovascular versus conservative therapy. *J Endovasc Ther* 2024;31:80-8.
37. Kim SR, Park TK, Choi SH, et al. Natural history of spontaneous isolated celiac artery dissection after conservative treatment. *J Vasc Surg* 2018;68:55-63.
38. Bhadra S, Drgastin RH, Song HK, et al. Lactate as a preoperative predictor of mortality in patients undergoing emergency type A aortic dissection repair. *J Pers Med* 2025;15:211.

Received: 27 October 2025; Accepted: 3 November 2025; Early view: 20 January 2026.

Contributions: all authors contributed to the literature search, writing, drafting, and reviewing of the manuscript, doing refinement of sections in alignment with journal guidelines. All authors approved the final version.

Conflict of interest: the authors declare no competing interests.

Ethics approval and consent to participate: the ethics committee deemed formal approval unnecessary, as no experimental procedures were performed and national and international therapeutic guidelines were followed. The study was conducted in accordance with the Helsinki Declaration. Clinical case concerns a patient admitted to the hospital and directly managed by the authors.

Patient consent for publication: informed consent was obtained from the patient for the publication of the clinical case.

Availability of data and materials: the clinical case data are available.

Publisher's note: all claims expressed in this article are solely those of the authors and do not necessarily represent those of their affiliated organizations, or those of the publisher, the editors and the reviewers. Any product that may be evaluated in this article or claim that may be made by its manufacturer is not guaranteed or endorsed by the publisher.

This work is licensed under a Creative Commons Attribution-NonCommercial 4.0 International License (CC BY-NC 4.0).